Journal of Orthopedics and Orthopedic Surgery

Original Article Open Access

The 'Floating Humeral Head', A Case Series of Combined Proximal Humeral and Glenoid Fracture Dislocations

Joshua CY Ong*, Mahmoud A Awadallah, Andrew J White, Paul M Robinson

Trauma & Orthopaedic Department, Peterborough City Hospital, Bretton Gate, UK

Article Info

Article Notes
Received: November 04, 2020
Accepted: December 24, 2020

***Correspondence:**
*Dr. Joshua CY Ong, Trauma & Orthopaedic Department, Peterborough City Hospital, Bretton Gate, UK; Email: joshua.ong@nhs.net.

Keywords:
Fracture
Proximal humerus
Glenoid fracture
Fracture dislocation
Shoulder
Open reduction internal fixation
Floating joint

Abstract

Background: Fracture of the proximal humerus combined with dislocation of the glenohumeral joint and a soft tissue or bony Bankart lesion are rare. Management options are largely surgical and different approaches to fixation have been described. The reported outcomes are generally poor.

Methods: We present a series of three rare cases of traumatic dislocations of the shoulder associated with combined fractures of the proximal humerus and glenoid that were treated with surgical fixation. We describe the surgical technique and clinical outcomes.

Results: Our patients had multiple medical comorbidities; and coupled with the burden of injury, made a slow post-operative recovery (mean Constant-Murley score of 48 points over a mean follow-up time of 20 months).

Conclusion: A high index of suspicion and appropriate imaging is required to properly diagnose and surgically manage this uncommon pattern of injury. We recommend surgical treatment of these severe injuries, to stabilise the glenohumeral joint, and to achieve optimal clinical outcomes.

Introduction

The shoulder is the most commonly dislocated large joint. Its dislocation occurs in 1–2% of the population[17]. Anterior shoulder dislocation accounts for 90–95% of all shoulder dislocationsAG[1]. The most common bony injuries associated with isolated anterior shoulder dislocation are Hill-Sachs lesions and corresponding bony Bankart lesions, followed by rotator cuff tears[3].

Depending upon the mechanism and severity of injury, a range of other fractures i.e. greater tuberosity fracture, humeral shaft fracture, coracoid fracture, humeral neck fracture, and avulsion fractures of anterior glenoid rim are possible[30]. Greater tuberosity fractures have been noted in 10-30% of shoulder dislocations[11]. Similarly, Bahrs et al. found that over 50% of greater tuberosity fractures were associated with traumatic anterior glenohumeral dislocation in a review of over 100 patients[4].

Sherif et al. reported on 9 patients that had concomitant anterior dislocations of the glenohumeral joint and fractures of the neck of humerus[27], without any bony injury to the glenoid. Fracture dislocations of the shoulder can be associated with soft tissue or bony Bankart lesions, but it is a rare occurence[24]. Robinson et al. found 3 bony Bankart injuries in their group of 58 consecutive fracture dislocations of the proximal humerus[24]. Surgical fixation of these injuries was only for the humerus and not the glenoid.

Avulsion fractures (the so-called chip fractures[32]) of the anterior inferior glenoid rim occur by a mechanism of shoulder abduction and external rotation at the time of dislocation[3,30]. Large glenoid fractures can cause shoulder instability, that increases if the fracture involves one-fifth or more of the anterior part of the glenoid cavity or if the size of fragment is greater than half of the largest diameter of the glenoid[2].

Combinations of these injuries are rare, and we present three patients with this pattern of injury as contribution to the literature.

Material and Methods

Three patients, age range 50 to 68 years old, presented consecutively to our hospital with this pattern of injury between 2015 to 2017.

Initial management entailed standard assessment, resuscitation and stabilisation of systemic problems according to advanced trauma life support (ATLS) principles. During the secondary survey, the neurovascular status of the affected limb was assessed, and the fracture dislocation was confirmed by radiographs. Confirmation of a fracture dislocation of the shoulder lead to an urgent Computer Tomography (CT) scan (Figure 1A-C) and preparation for surgical management on the next available shoulder operating list. 3D reconstructions in the axial, coronal and sagittal planes and volume rendered 3D reconstructions allowed assessment of the direction of dislocation, tuberosity displacement, and glenoid fracture size[5]. Closed reduction with sedation in the emergency department was not possible for due to the complete joint dislocation associated with fracture, and treatment proceeded straight to open reduction and internal fixation on the next available emergency list the next day (less than 24 hours).

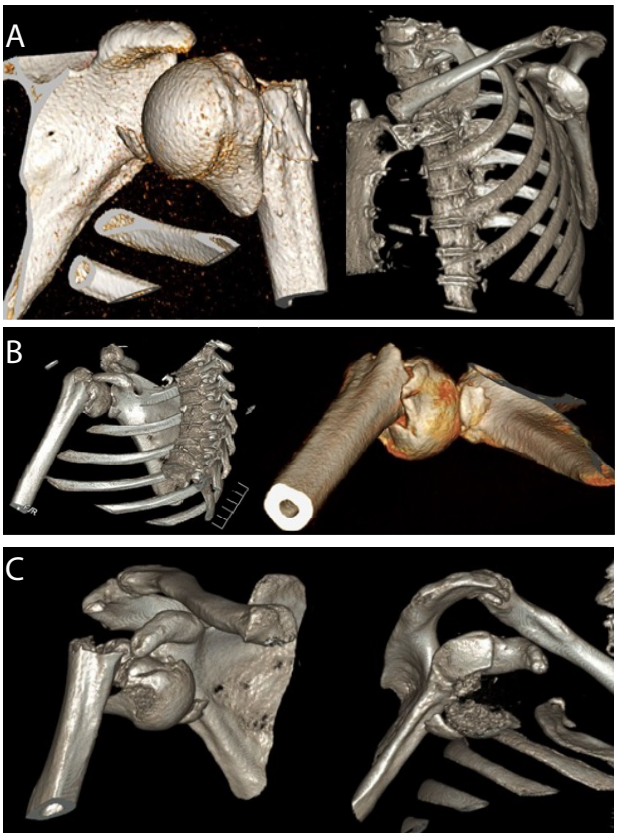

Figure 1A (Patient A pre-operative 3dimensional CT reconstructions)
Figure 1B (Patient B pre-operative 3dimensional CT reconstructions)
Figure 1C (Patient C pre-operative 3dimensional CT reconstructions)

The patients were relatively young but had poor American Society of Anaesthesiologists (ASA) scores of 2-3. All three patients had significant comorbidities. They all sustained low energy injuries by a fall from standing height, with an isolated injury to their dominant side. Medical co-morbidities are listed in table 1.1.

All patients underwent a general anaesthetic augmented with interscalene regional nerve block. Patients were positioned in beach chair with the operated arm free. Intraoperative fluoroscopic screening was utilised throughout. Surgical exposure was achieved via the delto-pectoral approach. Post operatively the patients continued as inpatients for observations and analgesia and were discharged when safe and medically fit. Table 1.1 lists the patient demographics, injury pattern, treatments, and outcomes.

Table 1.1: Demographics and treatment pathway

Demographics	Patient A	Patient B	Patient C
Gender	Female	Female	Male
Age	67	68	50
Hand Dominance	Left	Right	Right
ASA	2	3	3
Comorbidities	Vasculitis, Scleroderma	Diabetes, CVA	Diabetes, Asthma
Fracture of Humerus (Neer)	3 part	3 part	4 part
Bankart Lesion type	Bony	Bony	Bony
Glenoid fracture displacement (mm)	13.5	16	13
Surgical Approach	Deltopectoral	Deltopectoral	Deltopectoral
Humeral Fixation	Fixed angle device & Rotator cuff repair	Fixed angle device & Synthetic bone graft	Fixed angle device
Glenoid Fixation	Cannulated screws	Glenoid anchors	Cannulated screws
Complications	Frozen Shoulder	None	Axillary nerve neuropraxia
Range of Movement Elevation	90	90	80
Range of Movement ER	10	20	10
Range of Movement IR	SIJ	SIJ	SIJ
Constant Scores (18 months)	41	35	68

Standard post-operative precautions were prescribed with a sling for six weeks, early elbow and wrist movement within the 'inner cone' only (i.e., restricted external rotation). Wound reviews at 10-14 days with radiographs at that time. Further routine follow-up and clinical assessments of pain, range of movement, function and radiological union were at three, six, twelve and eighteen months (Figure 2A-C).

Results

Patient A sustained a two part proximal humerus fracture with significant extension into the calcar region, and initially had fixation of the proximal humerus only with a Peri-Loc 3.5mm 5 Hole proximal humerus locking plate (Smith & Nephew, Memphis, TN). Intraoperative assessment of the rotator cuff revealed a full-thickness tear of both the supraspinatus and infraspinatus tendons.

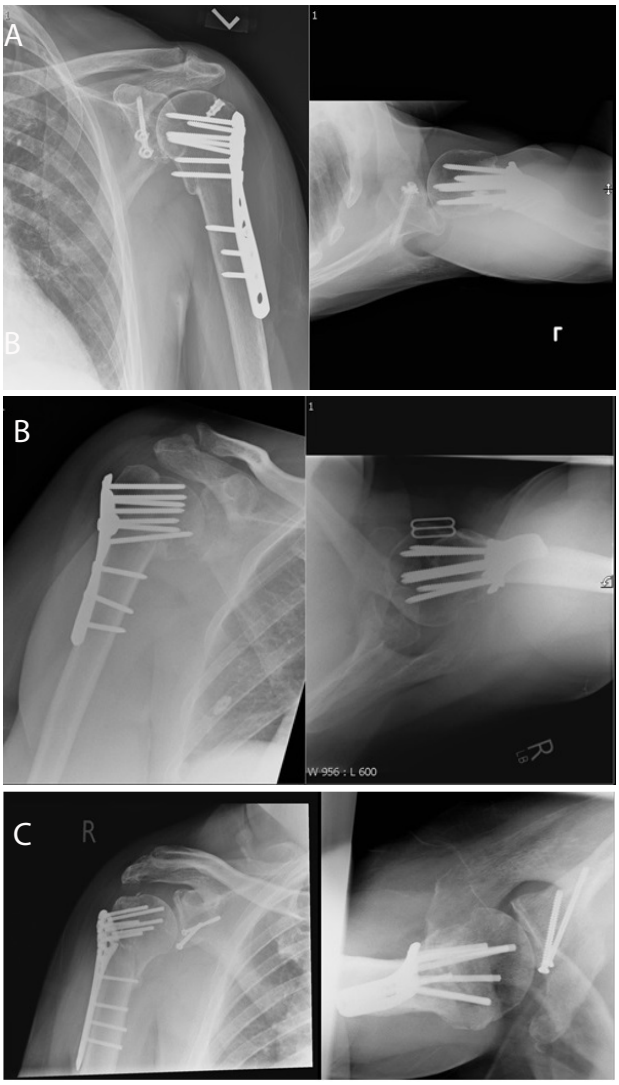

Figure 2A (Patient A radiographs at 6 months follow-up)
Figure 2B (Patient B radiographs at 6 months follow-up)
Figure 2C (Patient C radiographs at 6 months follow-up)

This was repaired at the same time with Fibrewire sutures (Arthrex, Naples, FL, USA) to the locking plate and one Corkscrew FTII suture anchor (Arthrex, Naples, FL, USA). The stability of the glenoid fracture was assessed intra-operatively and decision was to treat this conservatively, as the joint dislocation was attributed to the significant cuff tear. After 4 weeks, Patient A was discovered to have x-ray evidence of a anterior- inferior subluxation of the glenohumeral joint, and required a secondary procedure which involved reconstruction of the glenoid with an Eden Hybinette procedure using pelvic autograft. The glenoid was approached through a subscapularis splint in the mid portion, followed by a medial 'T' capsulotomy. Intra-operatively the glenoid fracture was noted to be 25-30% of the anterior-posterior diameter. The graft was fixed with a 2 hole wedged profile plate (Arthrex, Naples, FL, USA) and two 3.75mm cannulated compression screws. The capsulotomy was repaired with a Lupine BR anchor and Orthocord (DePuy Mitek, Norwood, MA).

Constant-Murley scores[6] of Patient A continued to slowly improve throughout follow-up (from 18 points at 6 months post surgery) but plateaued midway (41 points at 30 months post surgery). CT of the shoulder performed 36 months after the injury confirmed union of the glenoid bone graft, but signs of glenohumeral joint osteoarthritis.

Patient B sustained a three part proximal humerus fracture, which included a greater tuberosity fragment. Surgical management proceeded with fixation of the proximal humerus first, which provided a stable lever arm to approach the small glenoid bony Bankart through a subscapularis split. The glenoid fracture was noted too small for implant fixation, and was stabilised with two Orthocord suture loops (DePuy Mitek, Norwood, MA) around the fracture fragment and capsular-labral complex, reduced to peripheral Lupine BR anchor (DePuy Mitek, Norwood, MA) on the glenoid base[29].

On followup the patient experienced a meagre clinical improvement (from 15 points at 6 months post surgery) and plateaued in pain and function very early (35 points at 18 months post surgery).

Patient C had sustained a locked anterior fracture dislocation of the humeral head. Open reduction of the glenohumeral joint (GHJ) was difficult to achieve due to the discontinuity of the humeral head and shaft. The GHJ was reduced with traction sutures in the rotator cuff and by using a lever that was applied through the rotator interval. After GHJ reduction the humeral head was noted to be unstable and discovered to have tenuous glenohumeral capsular attachments that had avulsed off the unfractured part of the glenoid. The floating humeral head was too unstable for adequate proximal humeral fracture reduction, and therefore the GHJ was temporarily transfixed with a

1.6mm K-wire to aid stable reduction and plate fixation of the proximal humerus. Fixation was achieved with the Aptus 3.5mm Proximal Humerus Plate (Medartis, Basel, Switzerland). The glenoid was then approached via a transverse muscle split in the subscapularis and a 'T' capsulotomy. The glenoid fracture was reduced and fixed with two 3.5mm cannulated screws. The capsulotomy was repaired with Vicryl (Ethicon, UK) sutures.

Patient C was noted to have a post-operative axillary nerve and suprascapular nerve palsy that was not evident at the time of injury. Nerve conduction studies suggested a 'double crush' phenomenon from neurapraxia and a pre-existing severe C5/C6 cervical neck radiculopathy. There was a steady recovery to pre-injury levels of muscle power and sensation after six months. Patient C had significant early functional gains (40 points at 6 months post surgery) and a more gradual increase as the year progressed (68 points at 12 months post surgery). The mean Constant-Murley score for all three patients was 48 points.

Discussion

The 'floating shoulder' was described by Ganz and Noesberger in 1975, and further defined by Goss et al. as a double disruption of the superior shoulder suspensory complex[8,10].

Biomechanical concepts include structural integrity of the clavicle- acromioclavicular joint, scapular body junction and the clavicular-coracoclavicular ligaments-coracoid linkage. The anatomy of the shoulder becomes unstable, and may lead to problems with healing and function, and sometimes degenerative joint disease[22]. Hardegger et al. and Butters et al. recommended surgery in these cases, and other authors suggest initially fixing clavicle fractures before proceeding to the next component of the injury, if the complex remains unstable[13,14,19,20]. The 'triple dislocation fracture' was described in two articles[31,22]. This injury pattern involves anterior shoulder dislocation with concomitant fracture of the glenoid rim, greater tuberosity, and coracoid process[23]. Other concomitant injuries of the upper limb have been described. The 'floating arm' was described by Guven et al. and consist of a ipsilateral bony humerus fracture of both the proximal and distal ends[12,33,34,35]. The 'floating elbow' involves fractures of both humerus and ipsilateral forearm, with an unstable elbow joint[28]. The 'floating forearm' was also described in a case report of an elbow dislocation with ipsilateral distal radius and ulnar fractures, and the paediatric patient requiring operative management. We believe that our patient cohort fit into this category of unstable simultaneous fractures, and can be considered a 'floating humeral head'.

The patient cohort at risk of these injuries (shoulder dislocations associated with isolated fractures of the humeral head, neck, tuberosity, or injury to the glenoid) is older than 40 years of age, first episode of dislocation, and high energy mechanism[7]. Emond et al. formulated a predictive model for these injuries; however there were almost a quarter of these patients that did not have pre-reduction radiographs due to young age, female gender and similar injuries in the past[7]. Rowe et al. also showed a five-fold increase in the probability of clinically important fracture associated with shoulder dislocation in patients aged 40 years or older[26].

We noted our three patients sustained low energy trauma due to falls from standing height, which were not part of their predictive model. This factor does reflect that low energy injury may be a surrogate for frailty, and also acts as an independent predictor in associated neurological injury demonstrated by Robinson et al. All our patients had multiple systemic comorbidities such as diabetes, and one of our patients did have a transient axillary nerve palsy, complicated by the presence of diabetic neuropathy[25].

Königshausen et al. classified glenohumeral combination fractures into groups according to the severity of each fracture, and suggested a treatment algorithm for these injuries, predominantly surgical treatment[18]. Our cohort of patients would correspond to their classification of Type 2 glenohumeral combination fractures, describing them as large anterior glenoid rim fracture and proximal humeral fracture.

There has only been one case report describing the detailed surgical management in a case of a fracture dislocation of the proximal humerus that was combined with a glenoid fracture[16]. The authors describe radiological union but did not include clinical and functional results. In all our cases surgery was the management of choice due to the instability caused by both the glenoid injury and loss of integrity in the lever arm of the humerus. It was felt that non-operative management would lead to poorer outcomes due to a combination of proximal humeral mal-union and glenohumeral instability with GHJ incongruity and the potential for degenerative change. In regard to the glenoid injury, our patients were classified as Ideberg Type 1A[15] (Mayo modification[21]). The significant displacement (more than 4mm articular step off and gap) influenced the decision for surgical fixation. Furthermore, our patients did have expectations to return to high level of independence and function.

The surgical approach was by the anterior approach to the shoulder via the delto-pectoral interval for both the humeral and glenoid fixation. The sequence of fixation for this injury triad has never been described in the literature, and we propose starting with the proximal humerus fracture first, followed by the glenoid fracture. If the floating humeral head cannot be controlled with rotator cuff sutures, it can be transfixed temporarily with a Kirschner

wire. The glenohumeral joint was exposed by splitting the subscapularis muscle in the plane of the muscle fibres. We found that a single delto-pectoral approach was adequate for fixed angle plate osteosynthesis of the humerus, with sutures in the tendinous cuff allowing the implant to parachute down to the humeral head, aiding reduction.

We noted the early functional outcomes are poor for our patients, which are significantly lower compared to patients that experience proximal humeral fracture fixation alone[31]. These were a combination of capsular stiffness and global muscle weakness, and physiotherapy did not lead to significant functional gains, despite radiographic evidence of full bony union.

Higher rates of complications (fracture displacement, joint instability, heterotopic ossification, avascular necrosis, and implant loosening) are not uncommon to these combination fractures treated by surgical fixation rather than arthroplasty (e.g., Hemiarthroplasty or reverse shoulder replacement).

One of our patients (Patient A) with a glenoid fracture that was initially treated non-operatively, presented with early post-operative instability, and required subsequent fixation of the glenoid fracture. In retrospect a combined fixation of the proximal humerus fracture and glenoid fracture would have prevented late subluxation. Another option would be to undergo a reverse shoulder arthroplasty, providing there was sufficient bone stock for the glenoid component. Garofalo et al. reported good to excellent results in 26 patients treated with reverse shoulder arthroplasty, with the aid of a contoured glenoid bone graft during implantation[9].

Revision surgery due to loss of fixation is common, and occurred in two of the six patients reported by Plachel et al.[22], and does indicate the complexities of these injuries. This cohort of patients did have good Constant-Murley scores (mean 72), and reported being 'very satisfied' with their outcome, in contrast to our patients with very modest scores (mean 48).

The retrospective design of our study and the small case series with variable fracture patterns are limiting factors.

Conclusion

'Floating humeral head' injuries of the upper limb pose a significant surgical challenge to treat. Despite the rare occurrence, the clinician should first have awareness of the combination of these pathologies and the possible treatment options. Patients should be investigated with CT to detect glenoid fractures and quantify the articular component. From our experience we recommend combined early surgical management of both the proximal humerus and glenoid fractures utilising the delto-pectoral approach, without the need for a coracoid osteotomy. Fixed angle devices provide stable fixation of the proximal humerus, which should be approached first, facilitating glenohumeral joint reduction and glenoid exposure. This approach also allows rotator cuff sutures to facilitate reduction of displaced tuberosity fractures. Glenoid fractures may have better fixation with implants that produce fracture compression and rigid stability rather than anchors, and this may help to avoid late displacement. For irreducible fractures a reverse geometry shoulder arthroplasty should be considered. Patients have a guarded prognosis for long term outcomes, post- operative stiffness being more common than persistent instability, and patient expectations must be managed appropriately. Further research to evaluate the long term incidences of post traumatic arthritis, instability and avascular necrosis is required to further prognosticate the treatment of these rare injuries.

Funding

No outside funding or grants were received that assisted in this study.

Conflict of Interest

There are no conflicts of interest for the any authors, their immediate families, and any research foundation with which they are affiliated, including receiving royalties, stock or stock options, consultant agreements, or ownership from or with any commercial entity related to the subject of this work.

References

1. AG Apley, Apley's System of Orthopaedics and Fractures. ed. by 7th edn. Oxford, Anterior Glenohumeral Instability (Butterworth-Heinemann, 1993).
2. Aston JWJr, Gregory CF. 'Dislocation of the Shoulder with Significant Fracture of the Glenoid', J Bone Joint Surg Am. (1973; 55: 1531-3.
3. Atef A, El-Tantawy A, Gad H, et al. 'Prevalence of Associated Injuries after Anterior Shoulder Dislocation: A Prospective Study'. Int Orthop. 2016; 40: 519-24.
4. Bahrs C, Lingenfelter E, Fischer F, et al. 'Mechanism of Injury and Morphology of the Greater Tuberosity Fracture'. J Shoulder Elbow Surg. 2006; 15: 140-7.
5. Baudi P, Righi P, Bolognesi D, et al. 'How to Identify and Calculate Glenoid Bone Deficit'. Chir Organi Mov. 2005; 90: 145-52.
6. Constant CR, Murley AH. 'A Clinical Method of Functional Assessment of the Shoulder', Clin Orthop Relat Res. 1987; 160-4.
7. Emond M, Le Sage N, Lavoie A, et al. 'Clinical Factors Predicting Fractures Associated with an Anterior Shoulder Dislocation' Acad Emerg Med. 2004; 11: 853-8.
8. Ganz R, Noesberger B. '[Treatment of Scapular Fractures]'. Hefte Unfallheilkd. 1975; 59-62.
9. Garofalo R, Brody F, Castagna A, et al. 'Reverse Shoulder Arthroplasty with Glenoid Bone Grafting for Anterior Glenoid Rim Fracture Associated with Glenohumeral Dislocation and Proximal Humerus Fracture'. Orthop Traumatol Surg Res. 2016; 102: 989-94.
10. Goss TP. 'Double Disruptions of the Superior Shoulder Suspensory Complex'. J Orthop Trauma. 1993; 7: 99-106.

11. Gruson KI, Ruchelsman DE, Tejwani NC. 'Isolated Tuberosity Fractures of the Proximal Humeral: Current Concepts'. Injury. 2008; 39: 284-98.

12. Guven M, Akman B, Kormaz T, et al. '"Floating Arm" Injury in a Child with Fractures of the Proximal and Distal Parts of the Humerus: A Case Report'. J Med Case Rep. 2009; 3: 9287.

13. Hardegger FH, Simpson LA, Weber BG. 'The Operative Treatment of Scapular Fractures'. J Bone Joint Surg Br. 1984; 66: 725-31.

14. Herscovici D Jr, Fiennes A G, Allgower M, et al. 'The Floating Shoulder: Ipsilateral Clavicle and Scapular Neck Fractures'. J Bone Joint Surg Br. 1992; 74: 362-4.

15. Ideberg R, Grevsten S, Larsson S. 'Epidemiology of Scapular Fractures. Incidence and Classification of 338 Fractures'. Acta Orthop Scand. 1995; 66: 395-7.

16. Jehan S, Akhi Baig NM, Tavitian J. 'Treatment of Shoulder Dislocation with Greater Tuberosity and Glenoid Fractures'. J Coll Physicians Surg Pak. 2016; 26: 997-99.

17. Kirkley A, Litchfield R, Thain L, et al. 'Agreement between Magnetic Resonance Imaging and Arthroscopic Evaluation of the Shoulder Joint in Primary Anterior Dislocation of the Shoulder'. Clin J Sport Med. 2003; 13: 148-51.

18. Königshausen M, Mempel E, Rausch V, et al. 'Combined Fractures of the Humeral Head and the Glenoid'. Obere Extremität. 2019; 14: 118-26.

19. KP Butters. 'The Scapula', in The Shoulder, ed. by Matsen FA Rockwood CA (Philadel- phia: WB Saunders, 1990), pp. 335-66.

20. Kumar VP, Satku K. 'Fractures of Clavicle and Scapular Neck'. J Bone Joint Surg Br. 1993; 75: 509.

21. Mayo KA, Benirschke SK, Mast JW. 'Displaced Fractures of the Glenoid Fossa. Results of Open Reduction and Internal Fixation'. Clin Orthop Relat Res. 1998; 122-30.

22. Owens BD, Goss TP. 'The Floating Shoulder'. J Bone Joint Surg Br. 2006; 88: 1419-24.

23. Plachel F, Schanda JE, Ortmaier R, et al. 'The "Triple Dislocation Fracture": Anterior Shoulder Dislocation with Concomitant Fracture of the Glenoid Rim, Greater Tuberosity and Coracoid Process-a Series of Six Cases'. J Shoulder Elbow Surg. 2017; 26: e278-e85.

24. Robinson CM, Khan LA. Akhtar MA. 'Treatment of Anterior Fracture-Dislocations of the Proximal Humerus by Open Reduction and Internal Fixation'. J Bone Joint Surg Br. 2006; 88: 502-8.

25. Robinson CM, Shur N, Sharpe T, et al. 'Injuries Associated with Traumatic Anterior Glenohumeral Dislocations'. J Bone Joint Surg Am. 2012; 94: 18-26.

26. Rowe CR. 'Prognosis in Dislocations of the Shoulder'. J Bone Joint Surg Am. 1956; 38-A: 957-77.

27. Sherif MA, Ahmed NM, Ramy AD. 'Humeral Neck Fractures in Association with Traumatic Shoulder Dislocation'. J Ortho Bone Disord. 2017; 1: 000148.

28. Stanitski CL, Micheli LJ, 'Simultaneous Ipsilateral Fractures of the Arm and Forearm in Children'. Clin Orthop Relat Res. 1980; 218-22.

29. Sugaya H, Moriishi J, Kanisawa I, et al. 'Arthroscopic Osseous Bankart Repair for Chronic Recurrent Traumatic Anterior Glenohumeral Instability. Surgical Technique'. J Bone Joint Surg Am. 2006; 88 Suppl 1 Pt 2: 159-69.

30. te Slaa RL, Verburg H, Marti RK. 'Fracture of the Coracoid Process, the Greater Tuberosity, and the Glenoid Rim after Acute First-Time Anterior Shoulder Dislocation: A Case Report'. J Shoulder Elbow Surg. 2001; 10: 489-92.

31. Thyagarajan DS, Haridas SJ, Jones D, et al. 'Functional Outcome Following Proximal Humeral Interlocking System Plating for Displaced Proximal Humeral Fractures'. Int J Shoulder Surg. 2009; 3: 57-62.

32. Van Oostveen DP, Temmerman OP, Burger BJ, et al. 'Glenoid Fractures: A Review of Pathology, Classification, Treatment and Results'. Acta Orthop Belg. 2014; 80: 88-98.

33. Cervera TP, Roca L, Montalvo MÁM. 'Shoulder Dislocation with Head and Shaft Fracture Ipsilateral.' J Arthritis. 2016; 5: 194.

34. Chun JM, Pawaskar A, Jeon IH. 'Fracture dislocation of the proximal humerus with ipsilateral shaft fracture: a report of two cases.' Acta Orthop Traumatol Turc. 2013; 47(5): 370–5.

35. Zhu B, Micić I, Kim KC, et al. 'Ipsilateral humeral neck and shaft fractures'. Vojnosanit Pregl. 2017; 74(3): 261–266.